

ICOI
DIPLOMATE
ORAL EXAM

Case Presentation Format

- May be presented on a laptop in Powerpoint or Keynote, or a printout.
- There will be a minimum of 2 qualified Diplomate level examiners- they should not be from the same discipline (e.g one will be restorative, one surgical).
- 3 cases to be presented to examiners
 - One should have a complication that was overcome.
 - Selected cases should show an increased degree of difficulty e.g. a narrow ridge, highly aesthetic case
 - Particular attention will be paid to quality of clinical work and presentation.
 - Any questions relating to the case are valid, including choice of materials, surgical techniques, restorative decisions and maintenance plan.
- Examiners decisions are final. You may attempt the oral examination as many times as needed. If you fail you may request feedback on the presentations to help you improve for your next attempt.

Case Presentation Format

- You must sign a declaration it is all your own work, if not acknowledge others in presentation. Anyone found not presenting their own cases will be expelled from the process and banned from re-applying without refund of fees.

Case Presentation Guidelines

- Relevant Medical History
- Relevant Dental History
 - Chief concerns
 - History of current complaint
 - Periodontal status
 - Other relevant information (bruxism, etc)

Case Presentation Guidelines

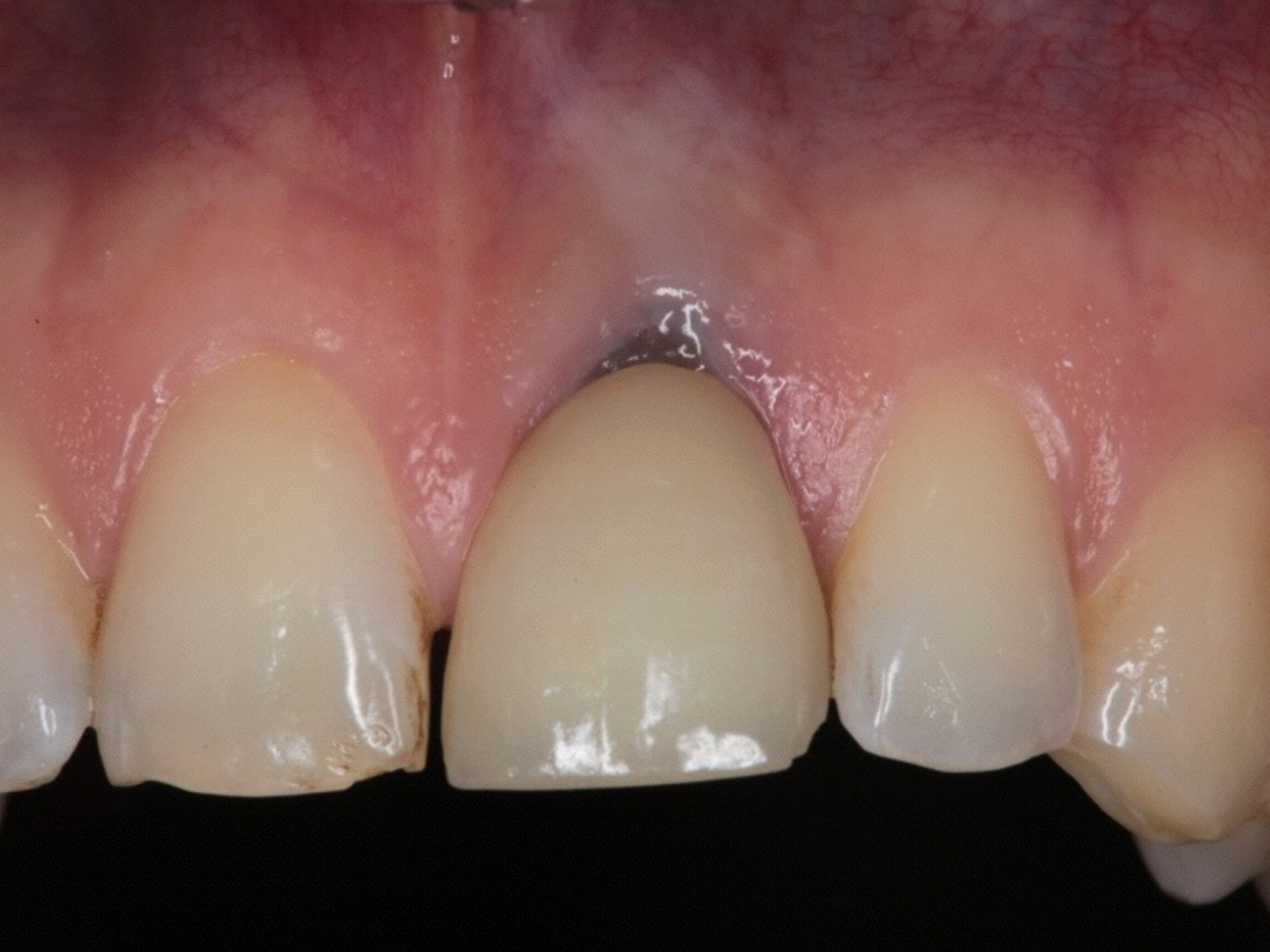- Pre operative photographs
 - Frontal at rest
 - Frontal at high smile
 - Retracted full arch frontal
 - Occlusal (retracted lips, taken in mirror)
 - Relevant close up of the area, teeth, ridge, etc
- Pre-operative radiographs
 - PA of area
 - OPG
 - CBCT if needed

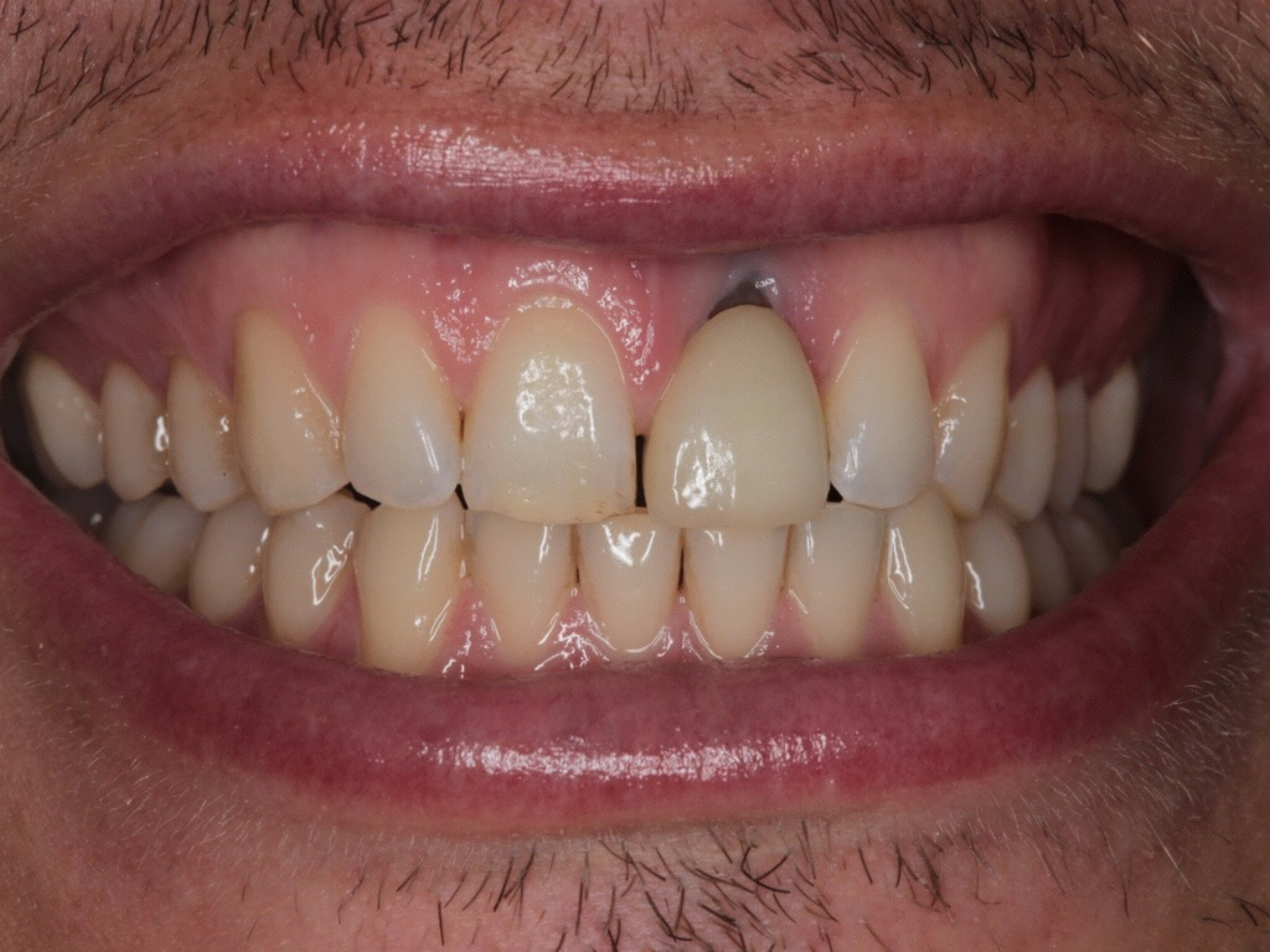Case Presentation Guidelines

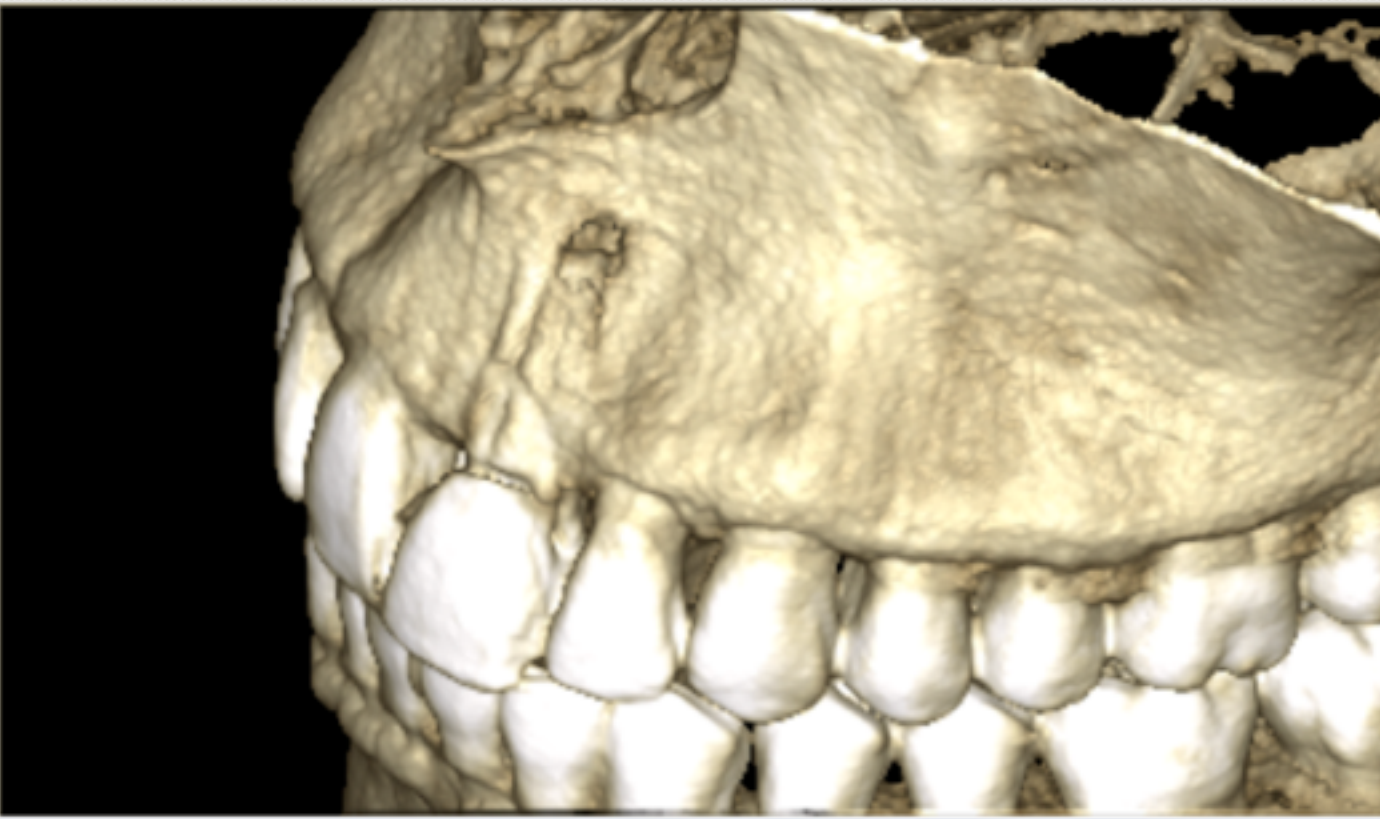
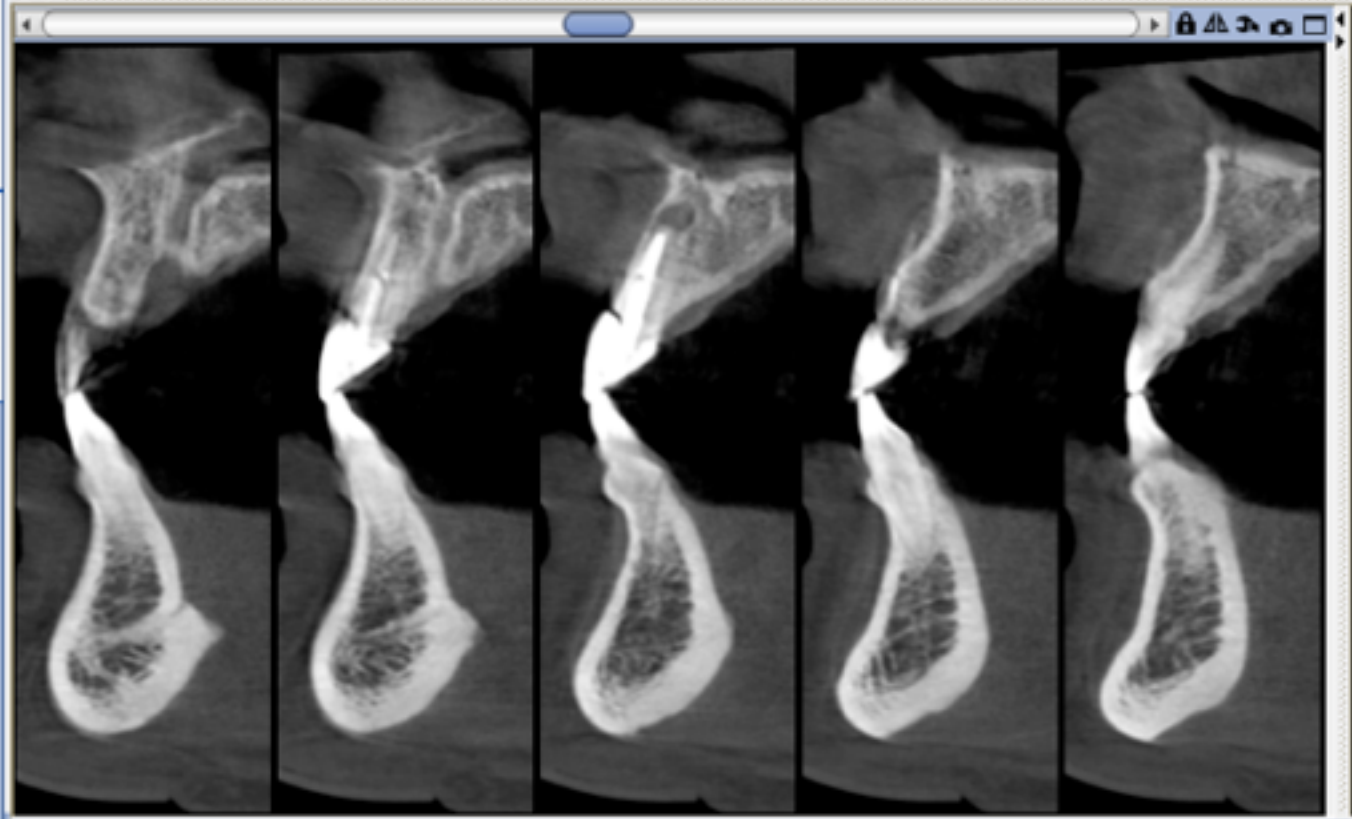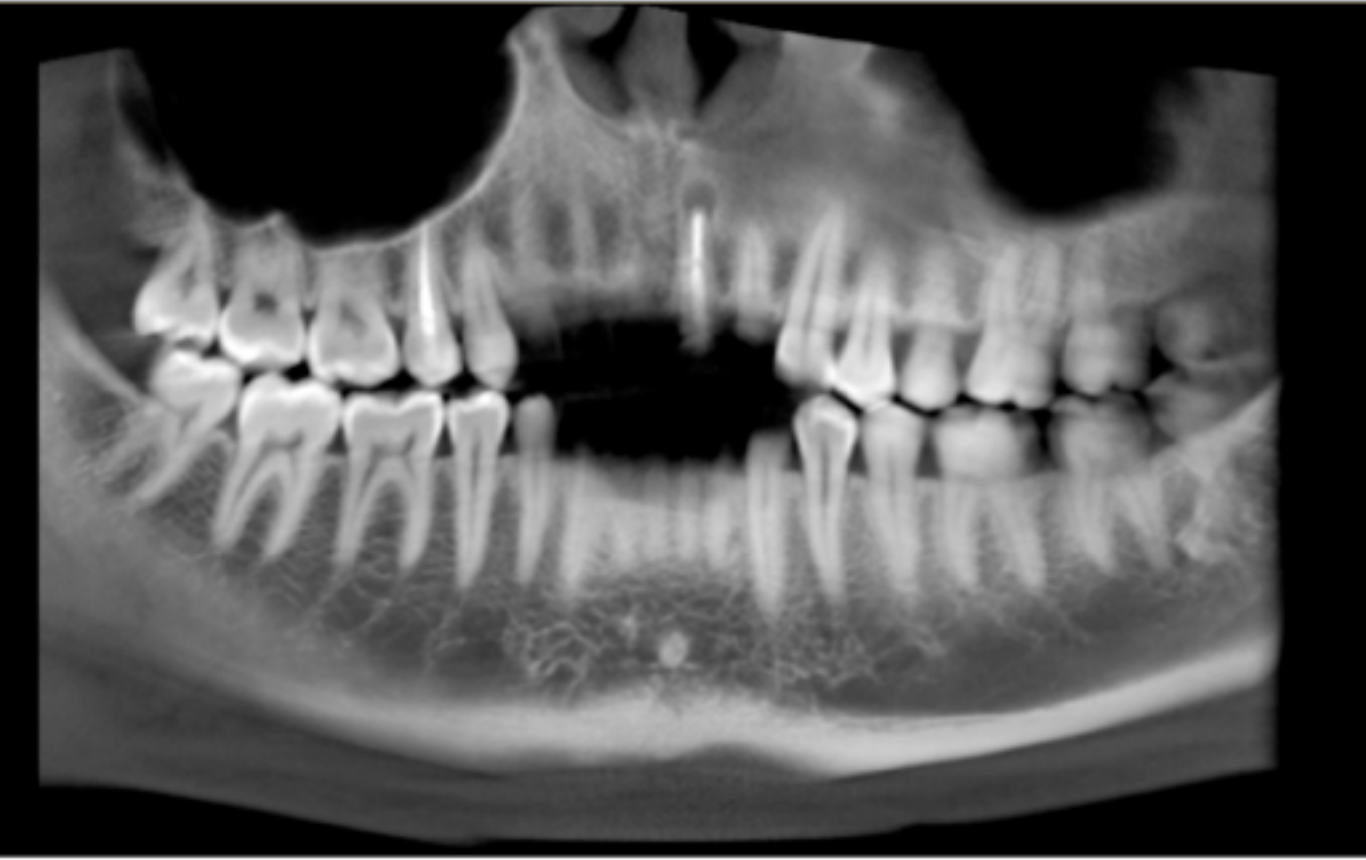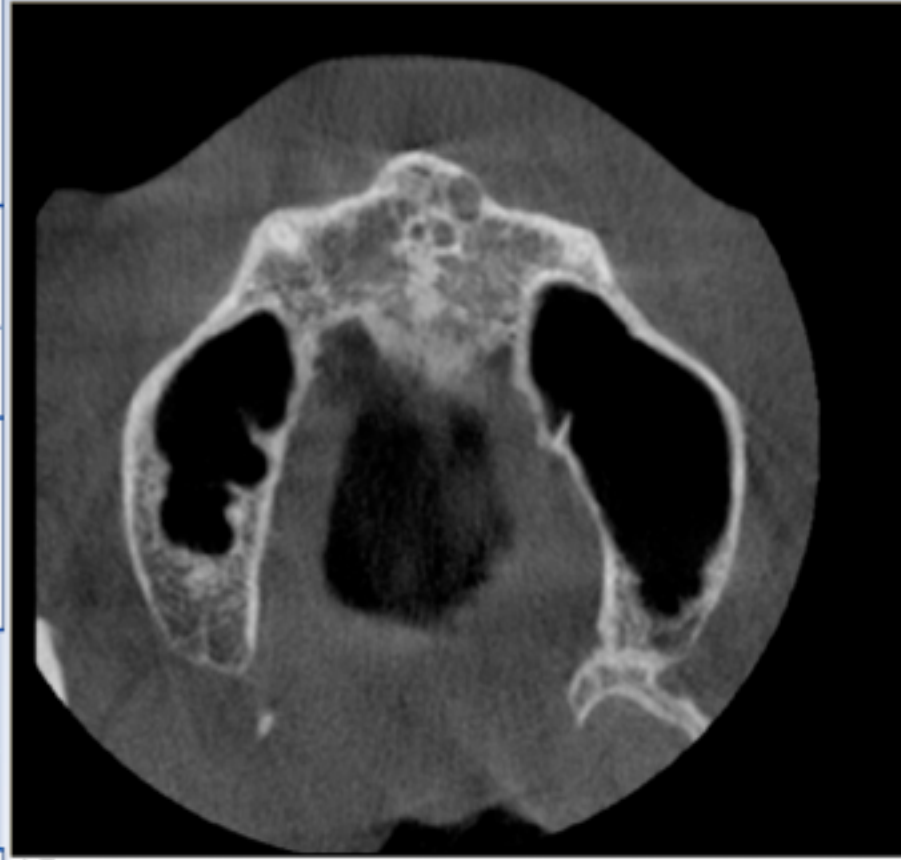
- Statement of Diagnosis and treatment options presented to patient
- Treatment planning
 - Radiographic workup
 - Prosthetic planning
 - Wax-up- traditional or digital
 - Aesthetic planning if required
 - gingival levels, crown size, shape, etc
 - Surgical guide if used
- Treatment photographs- surgical and healing as needed

Case Presentation Guidelines

- Post restorative photos
 - Healed, stable result
 - Close ups of area
 - Full smile photo
 - Photo in full occlusion
- Post-op Radiographs
 - PA
 - OPG, CBCT if necessary
- Summary of case
 - critical review
 - what was done well and why
 - complications and failures







PROBLEM LIST

- Vertical root fracture with abscess- bone loss
- Thin periodontal biotype
- High lip line- gummy smile
- Cosmetically conscious patient
- This is the one you have no control over!!!



